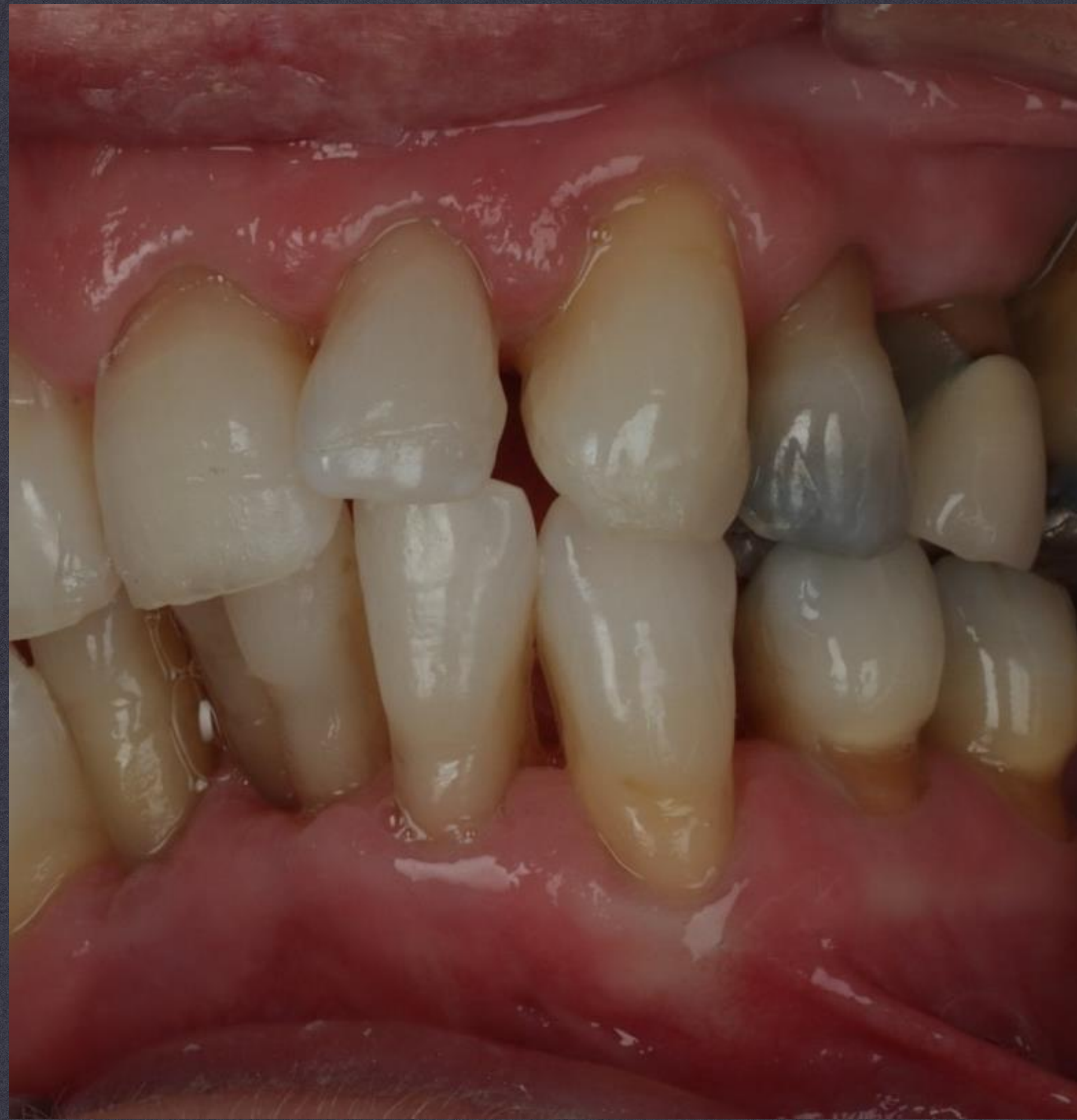
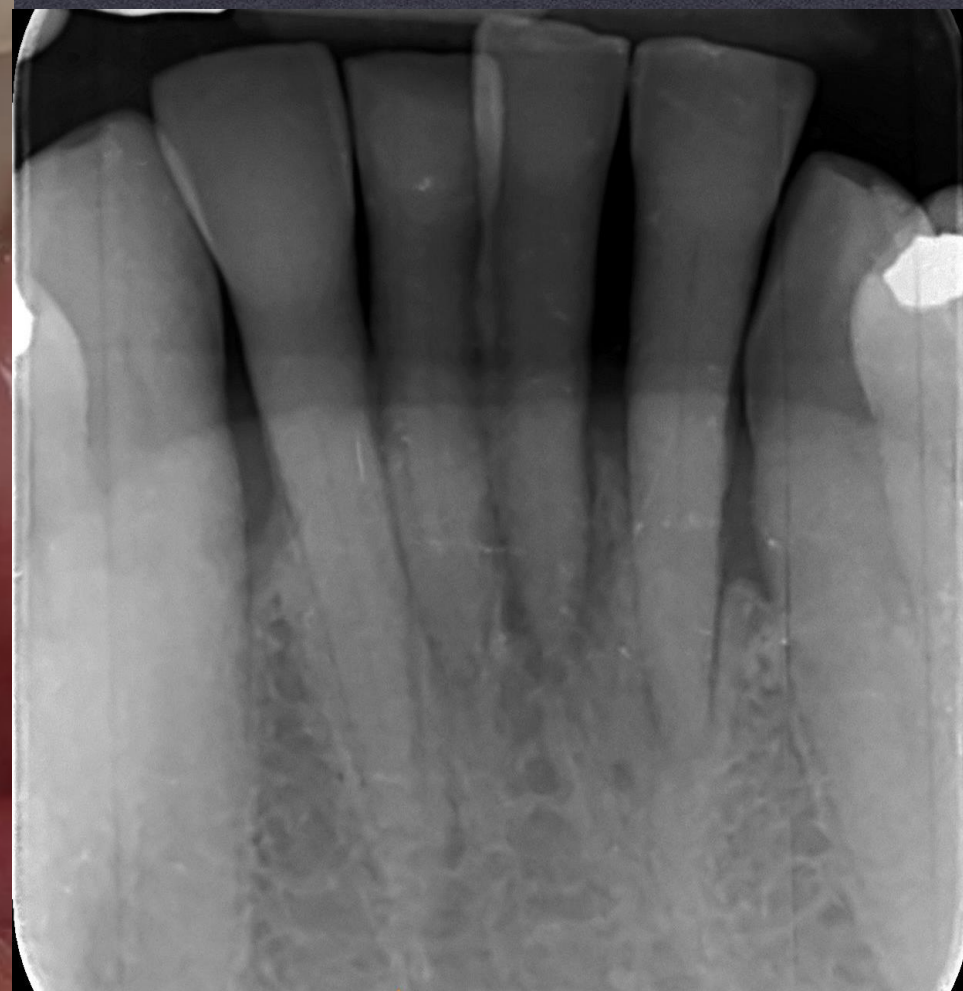
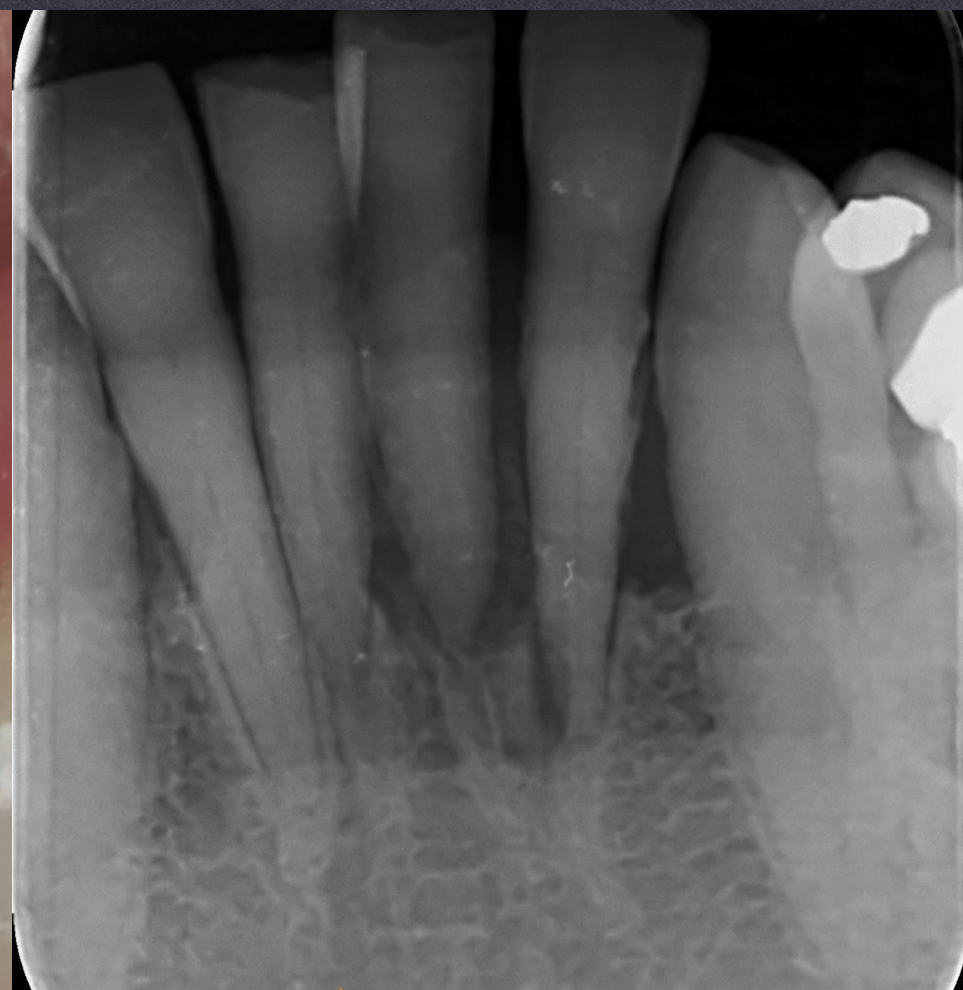
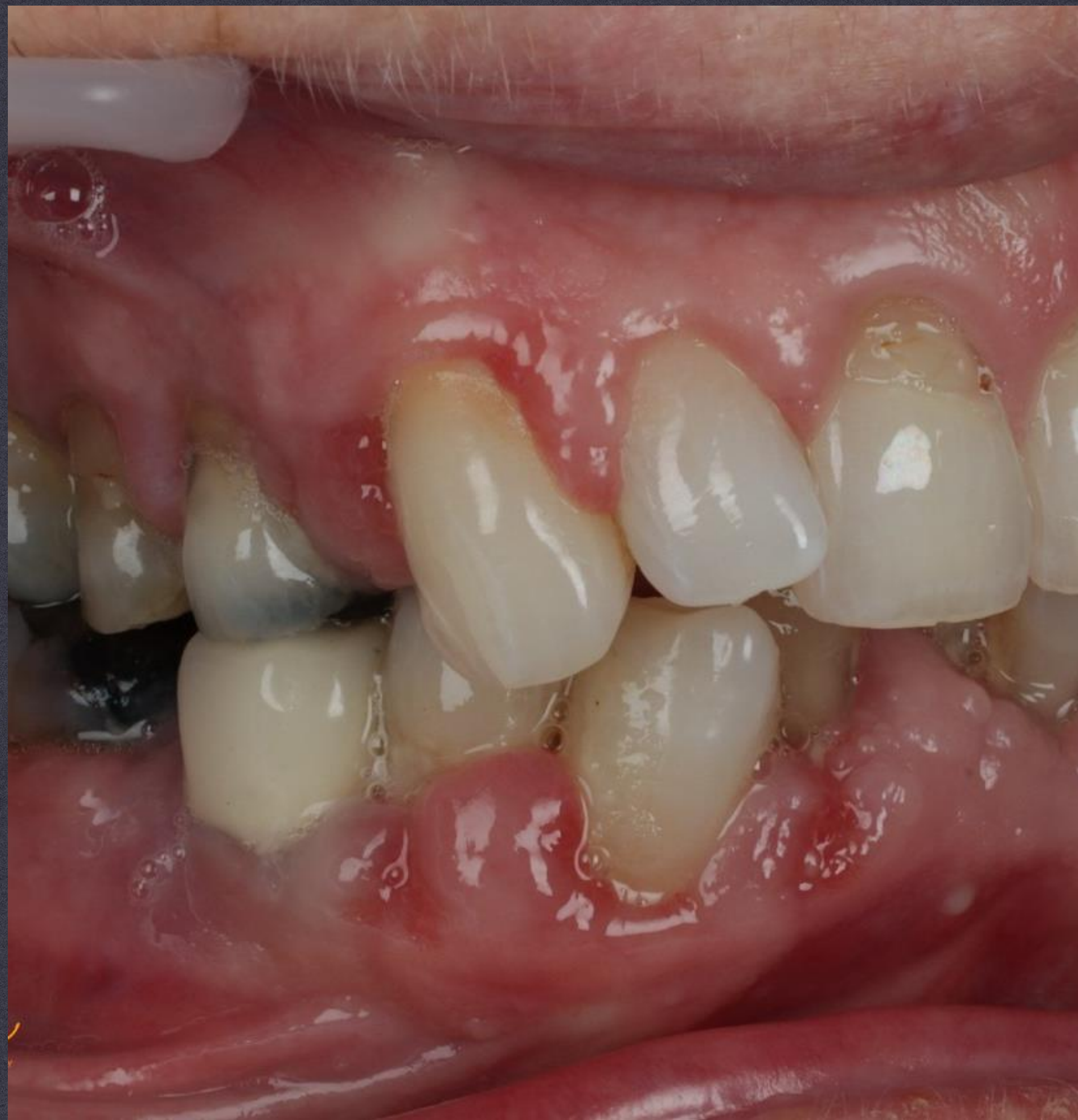
PROJECT

REVO NAP LASER TREATMENT FOR GUM DISEASE

DR DIX PREMSINGH PRASATH

DATE

30/03/2024

CLIENT

1

The elderly patient attended for extraction of loose lower front teeth and implant replacement

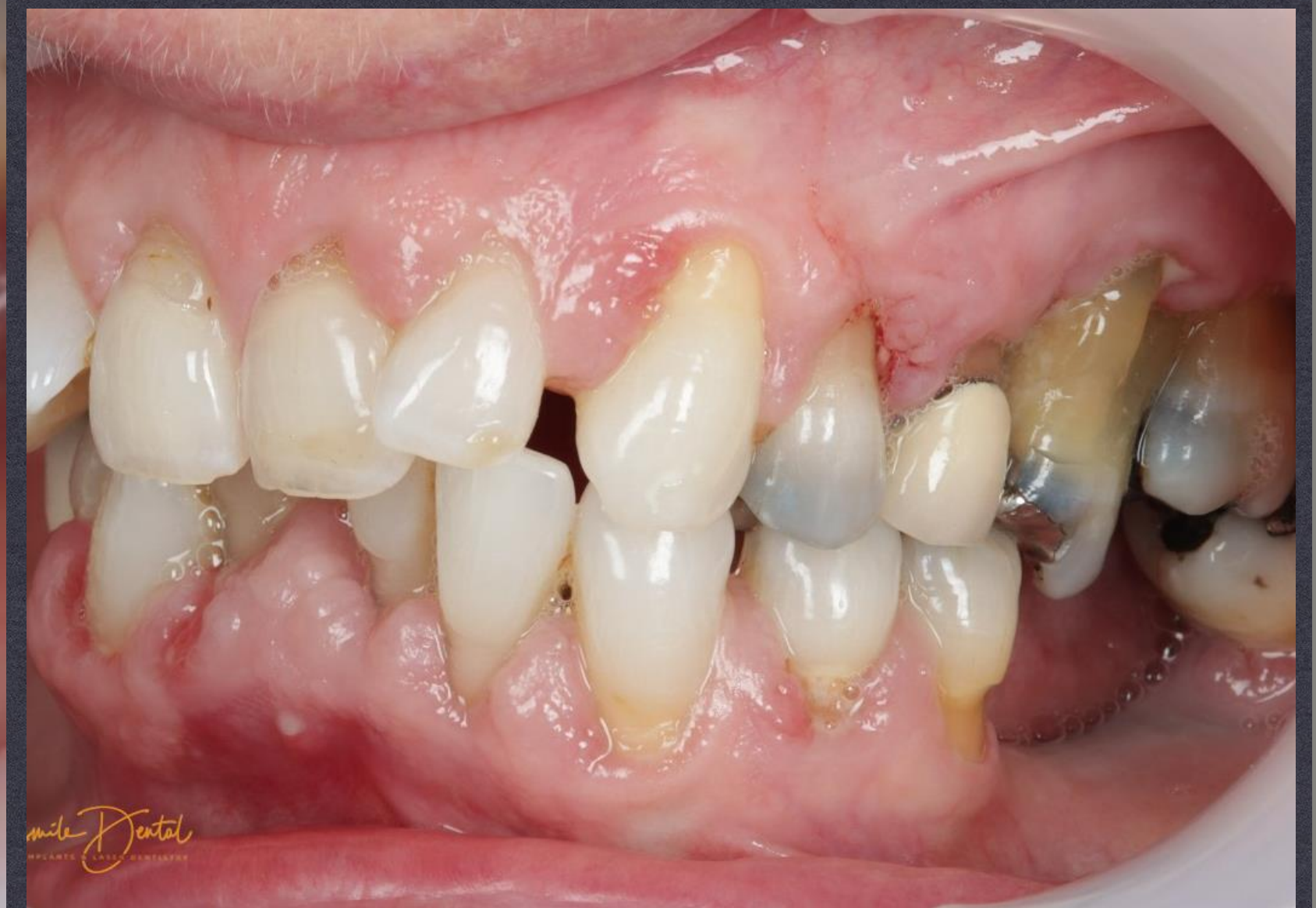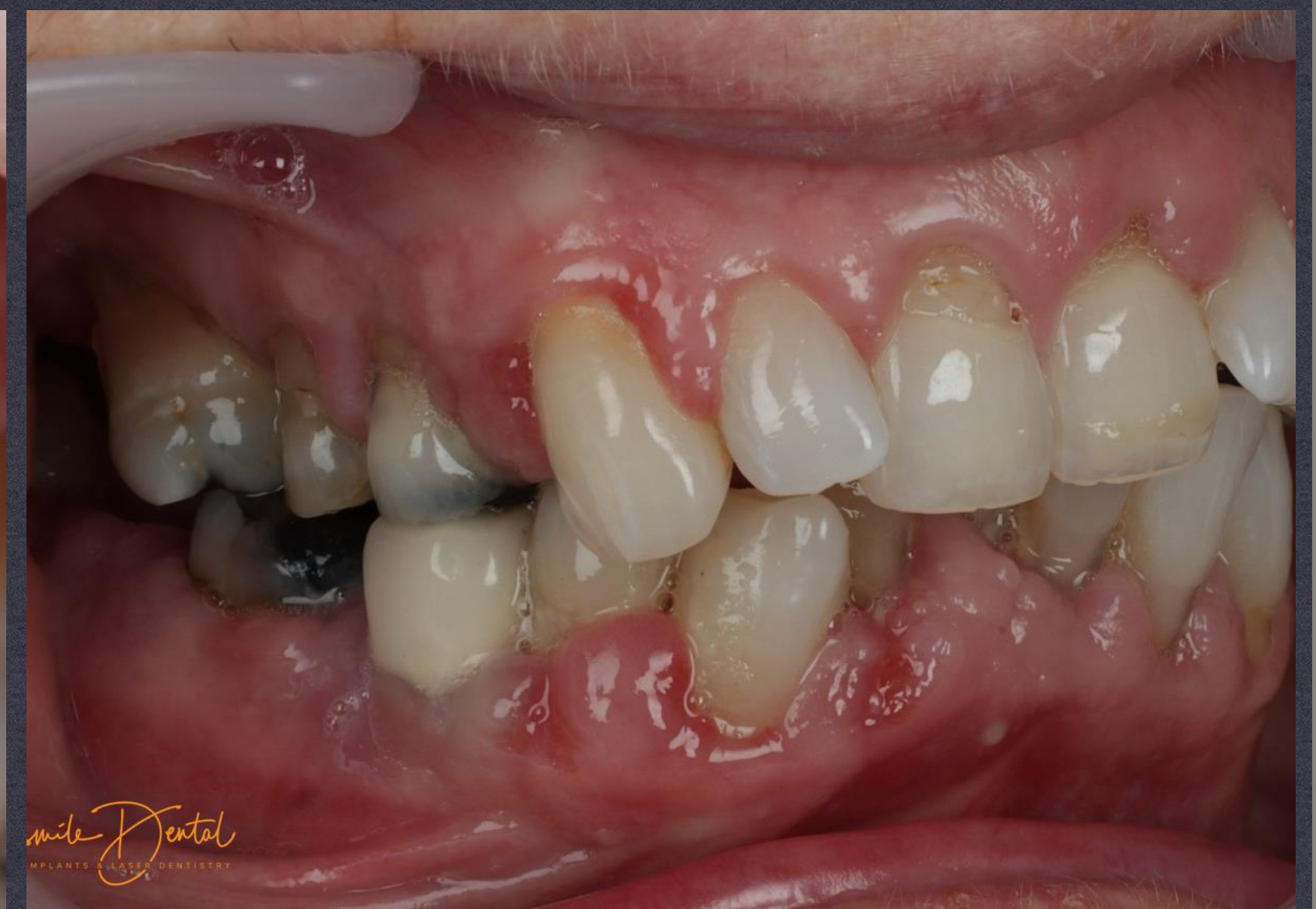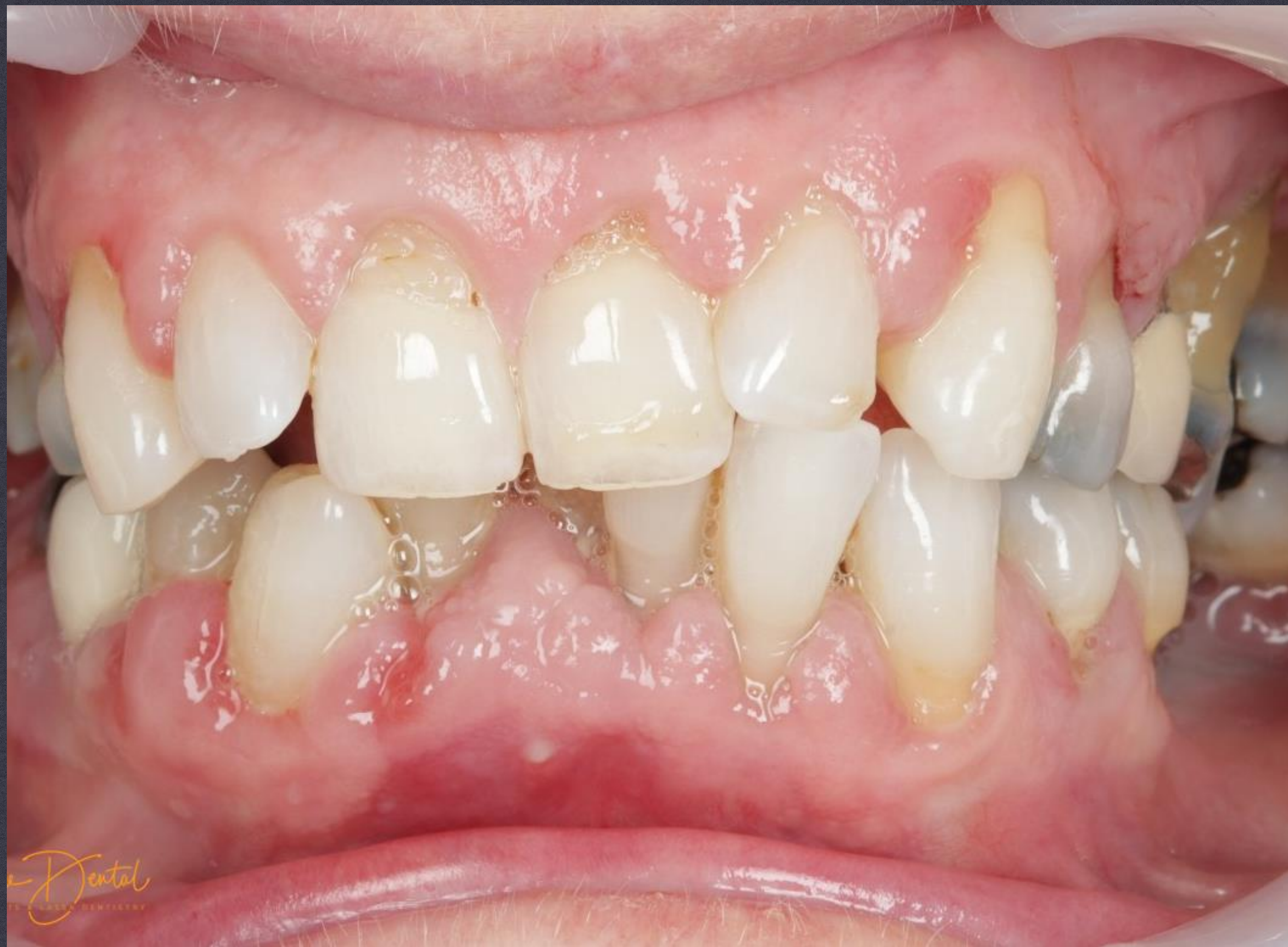Lower front teeth were infected and the patient couldn't close mouth. There was severe halitosis (bad breath), which the patient was concerned about as well.

This advanced periodontal disease condition was treated by our laser and dental implant surgeon Dr Dix Prem Singh Prasath using his unique REVO NAP (Revolutionized New Attachment Procedure) technique, where he uses multiple laser wavelengths and bespoke settings to achieve the desired results.

We managed to stabilize the teeth without the need to extract along with stopping halitosis.

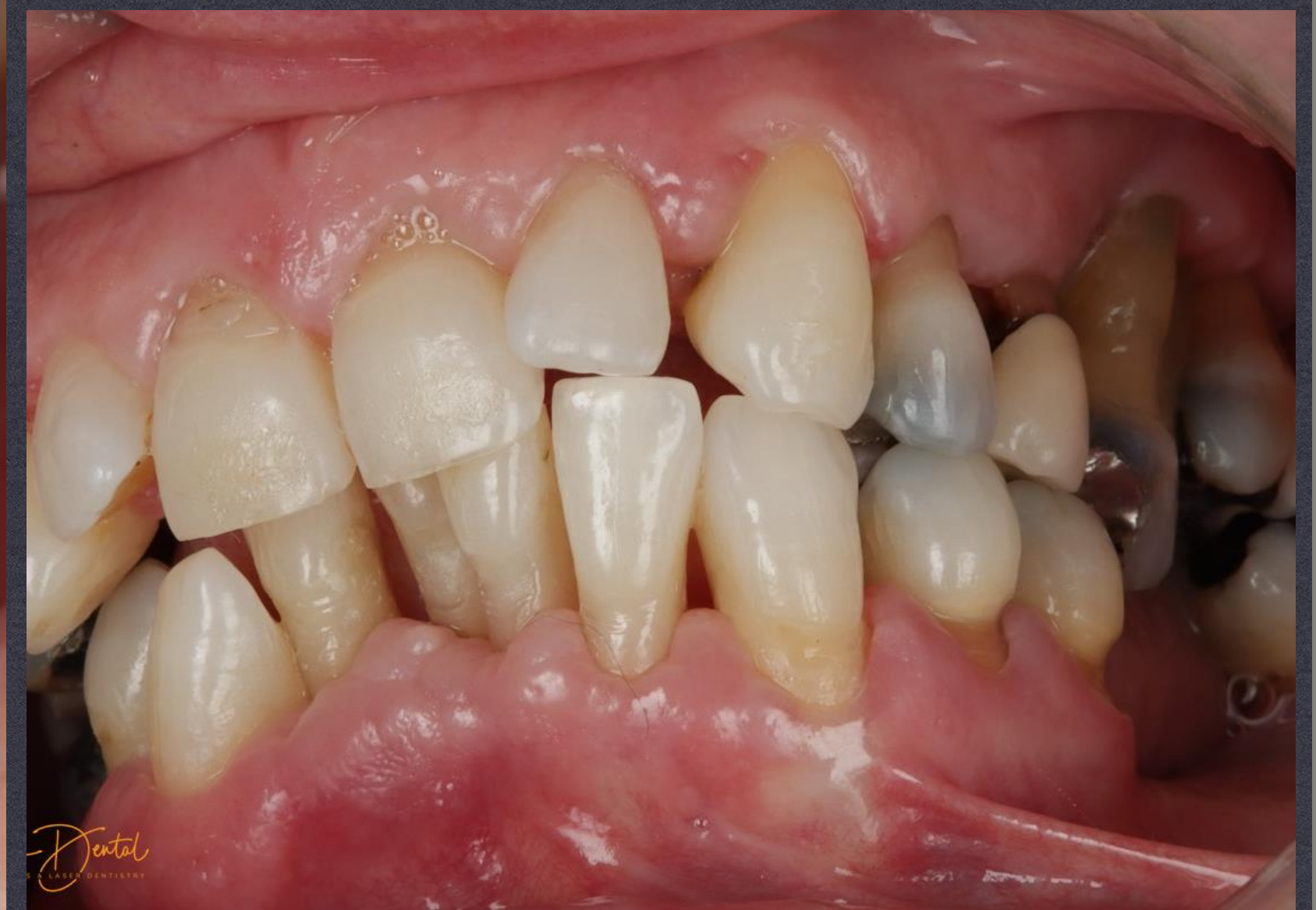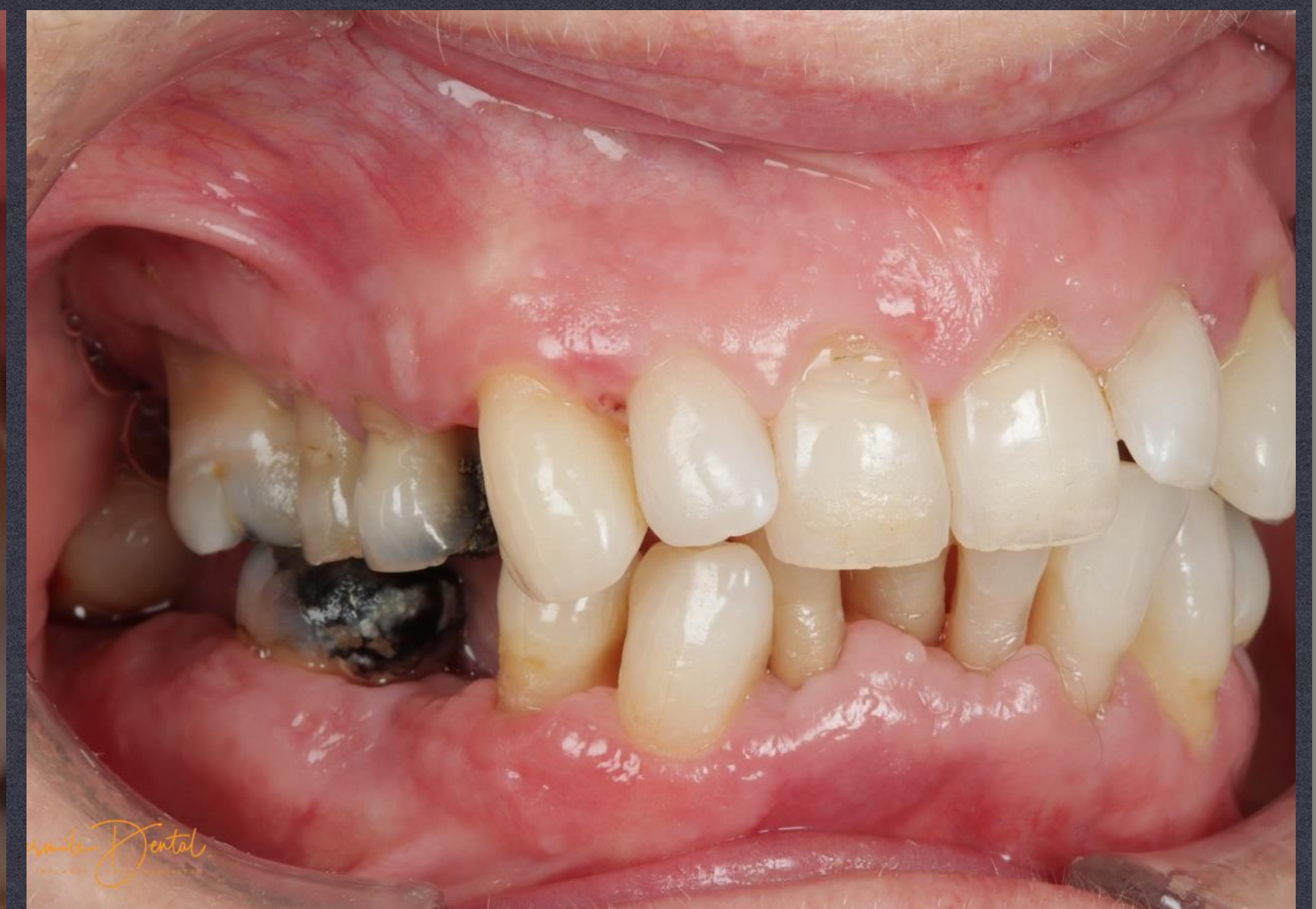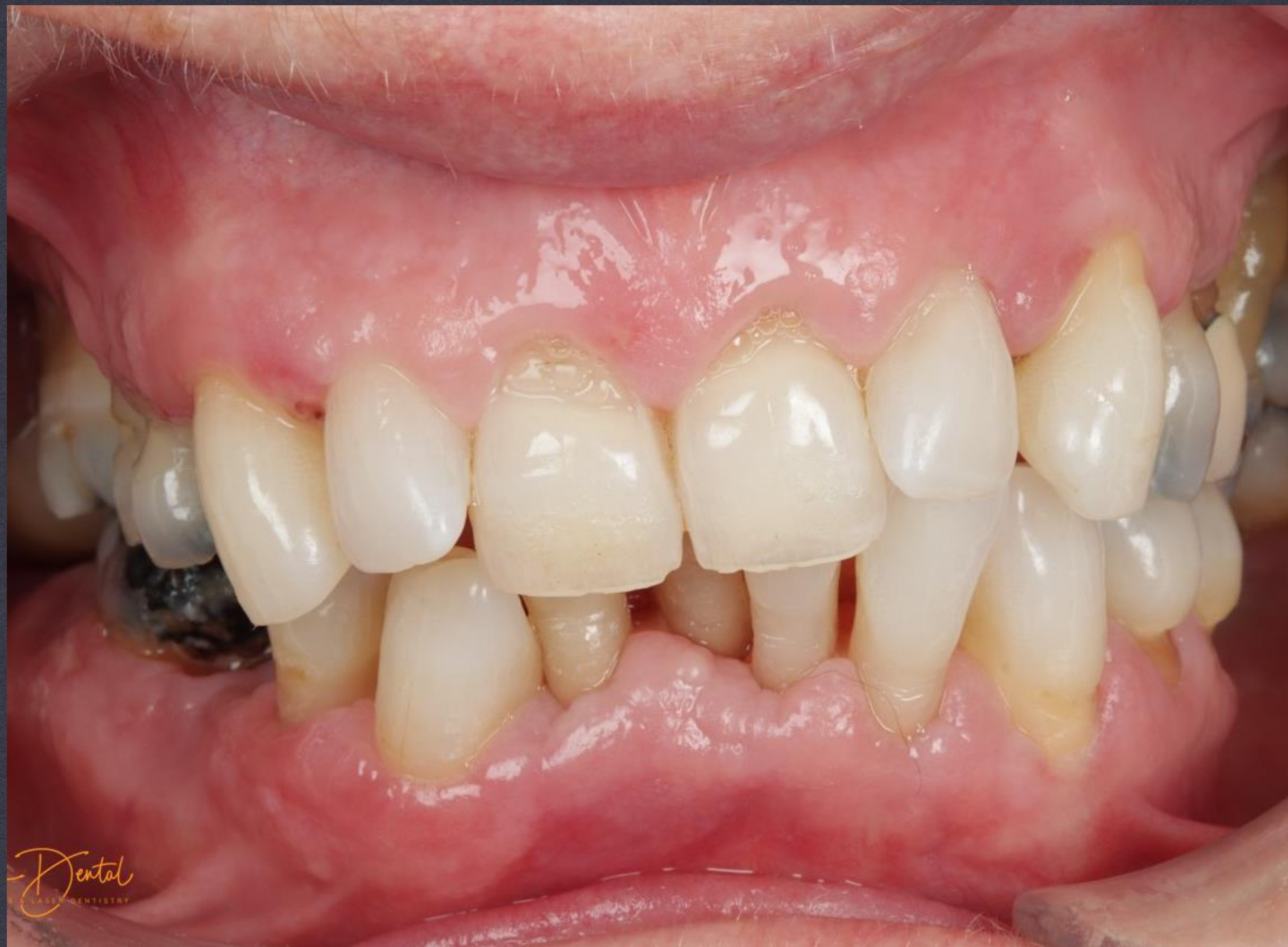Observe the before and after photos where the inflammation is completely eliminated, pus seen in before photos is completely eradicated.

We are excited to see bone regeneration in the region, which helped to stabilize the teeth (compare x-rays)

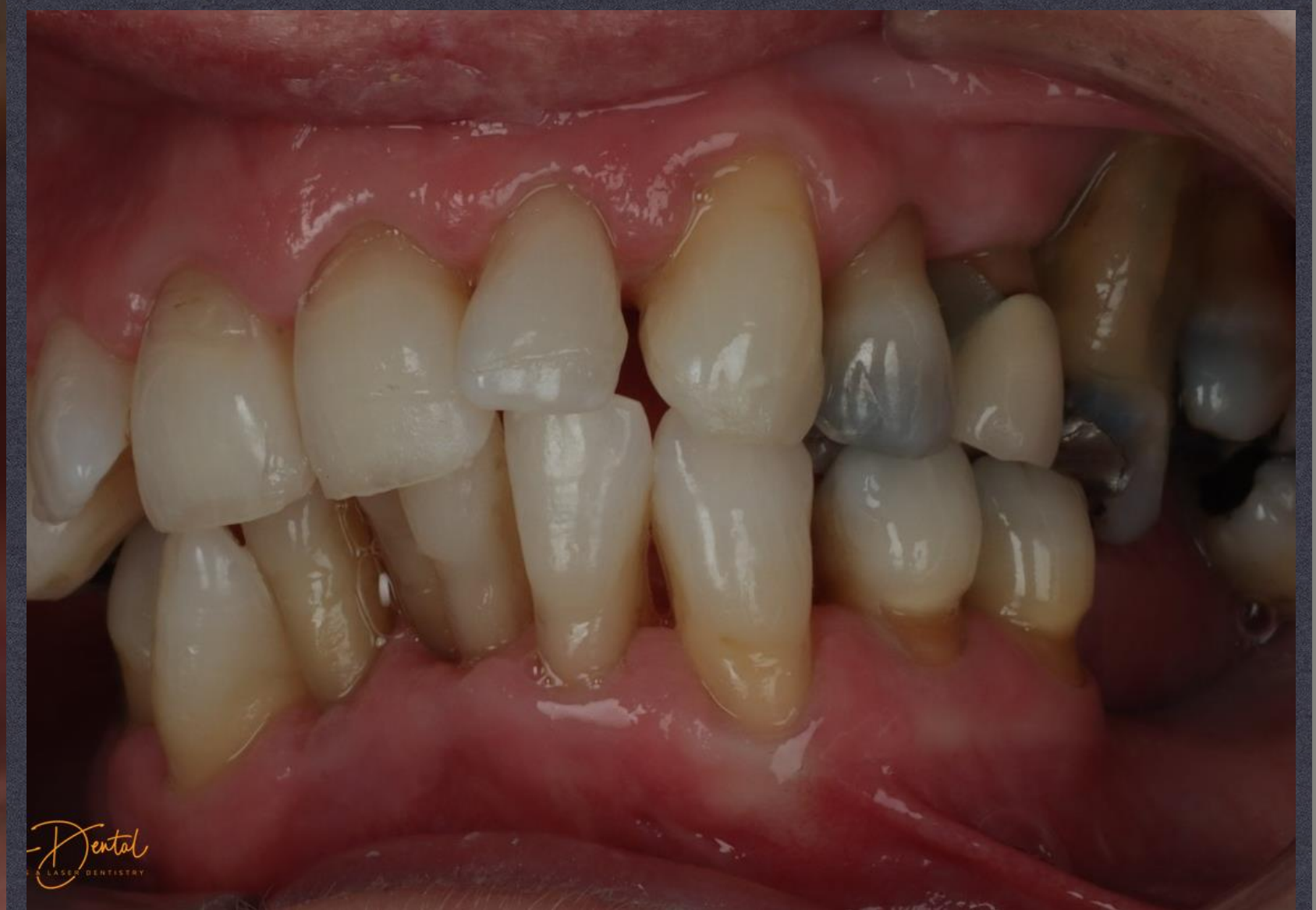
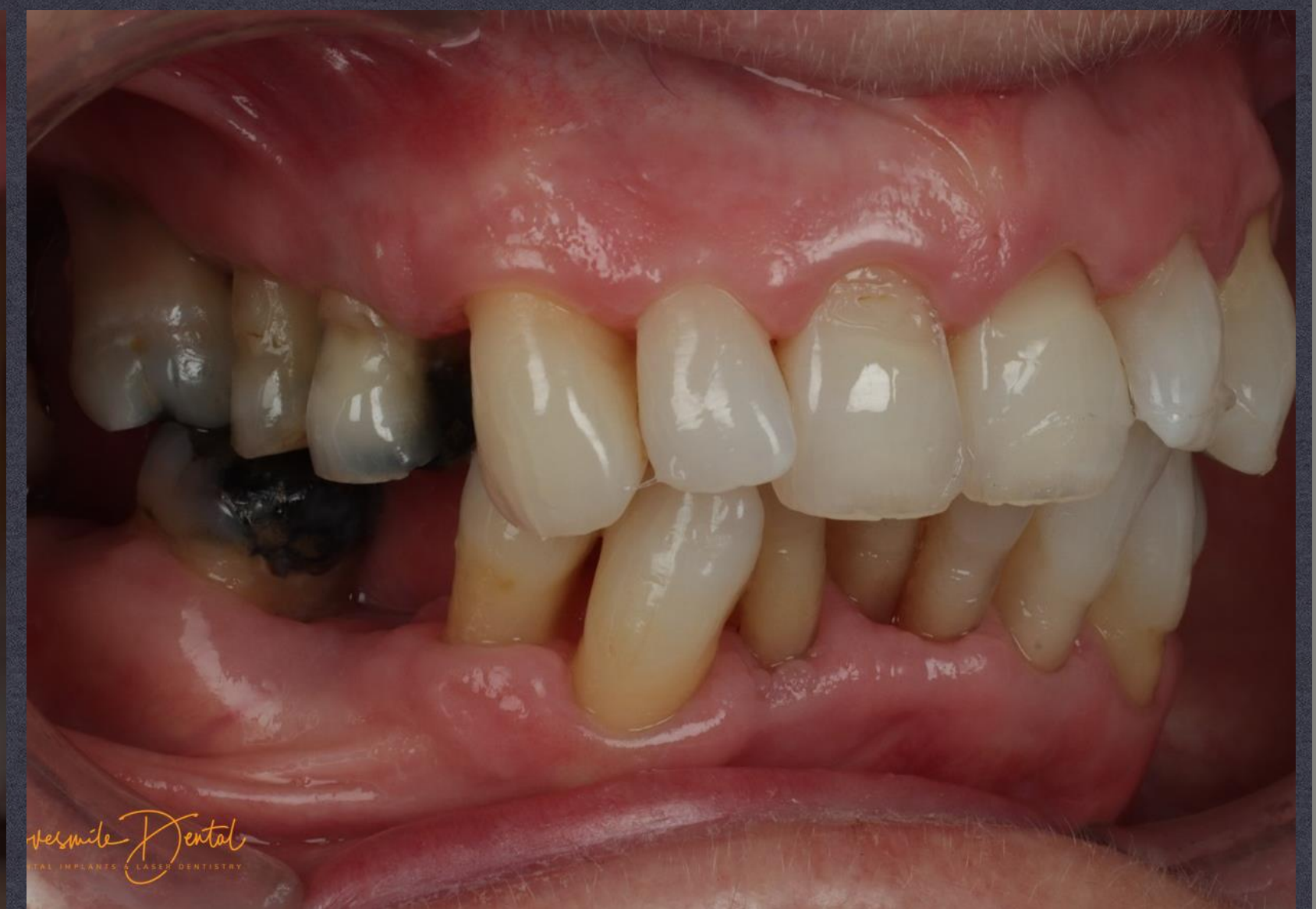
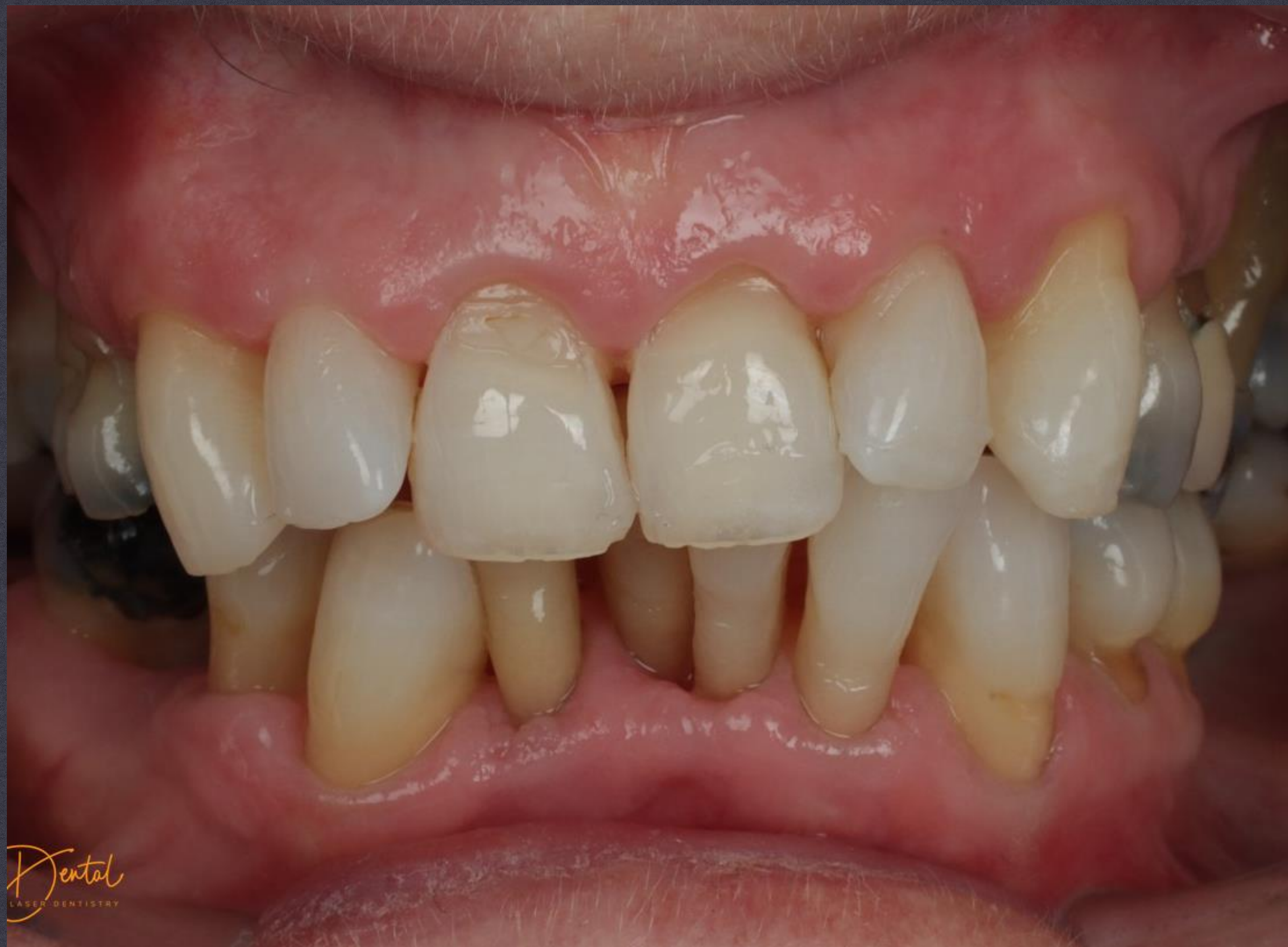BEFORE

OBSERVE SWOLLEN GUMS, PUS OOZING FROM FEW AREAS

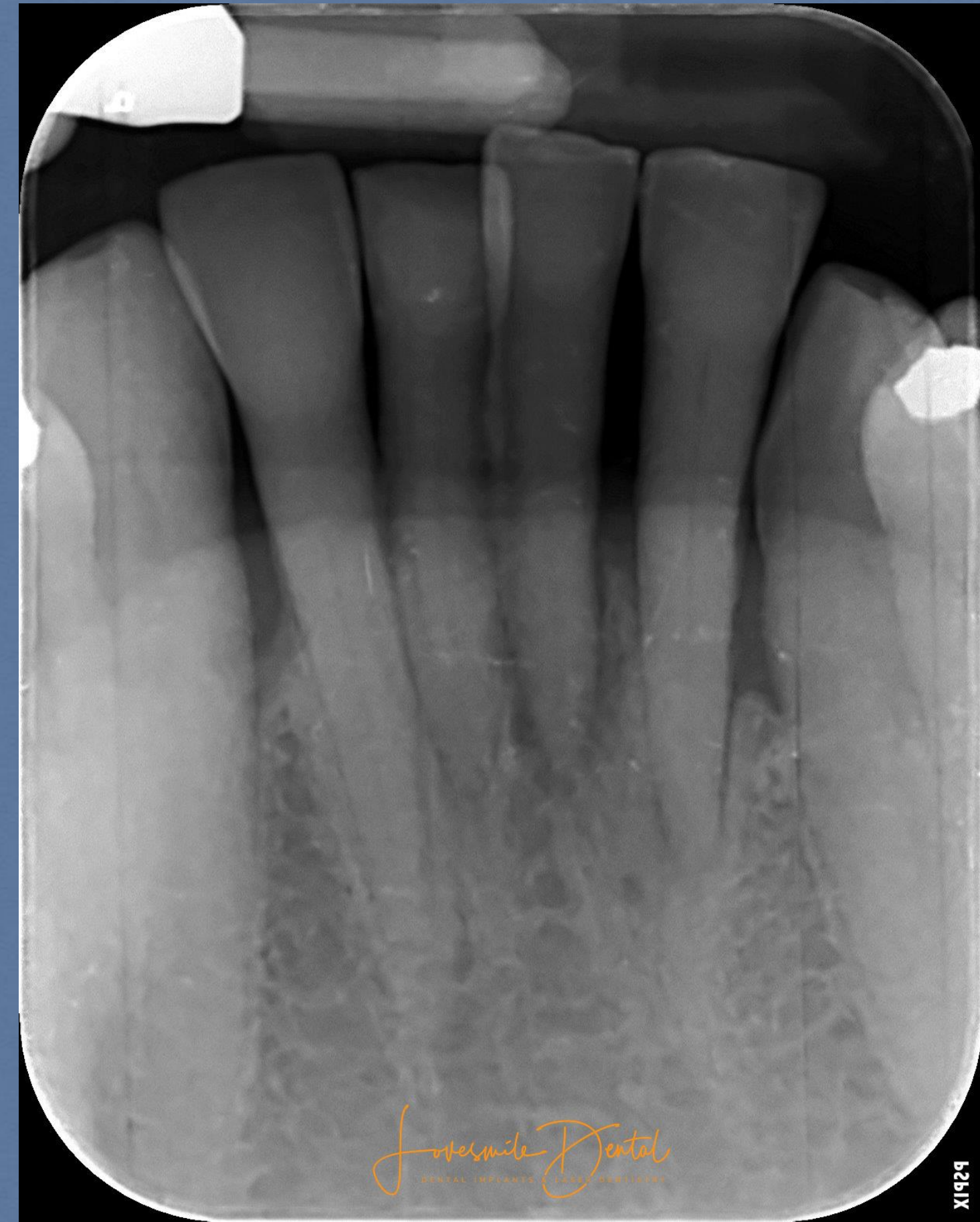
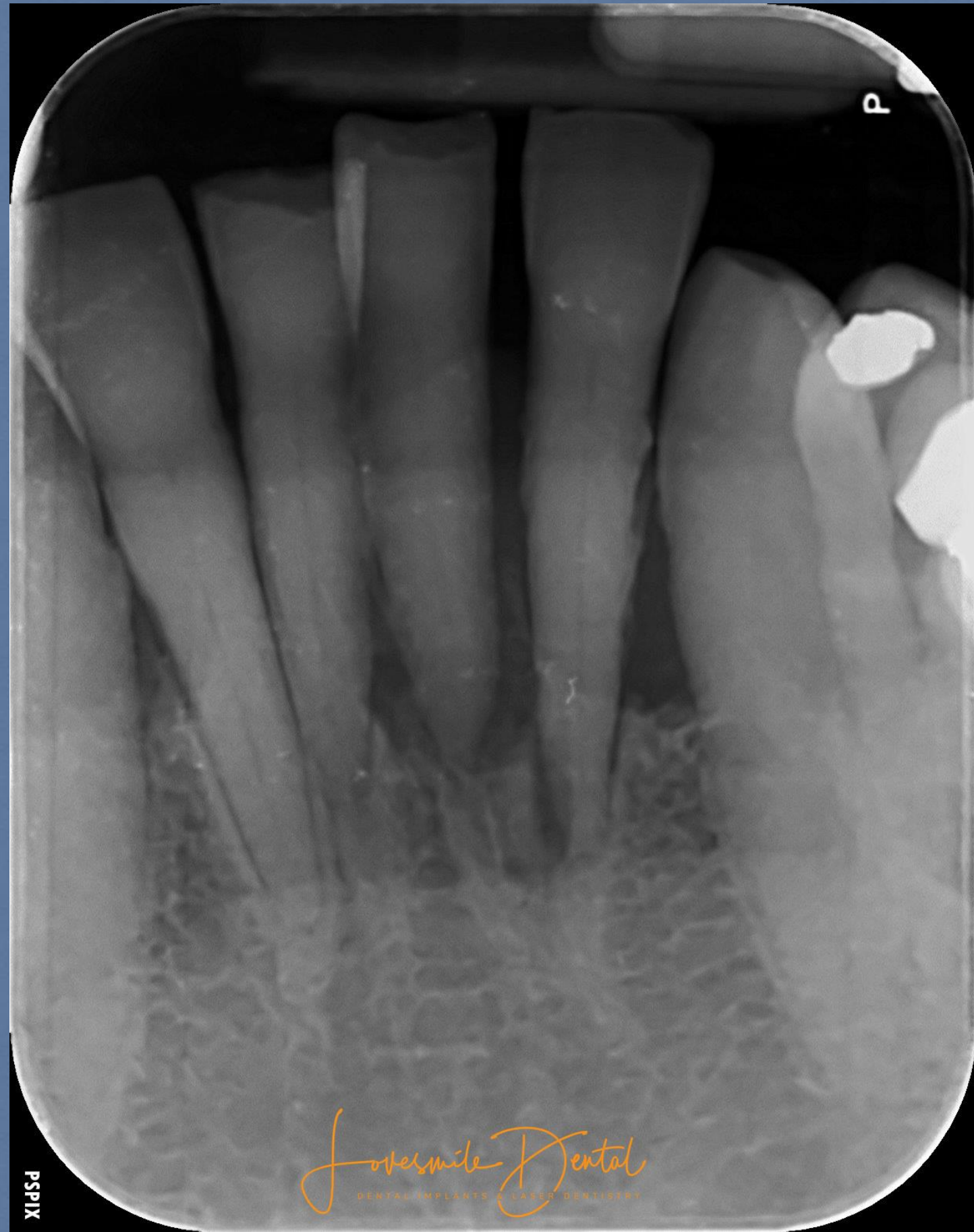

LOOK AT THE RAPID IMPROVEMENT WITH IN A WEEK OF LASER TREATMENT
SWELLING REDUCED, NO PUS DRAINAGE AND IMPROVED GINGIVAL HEALTH

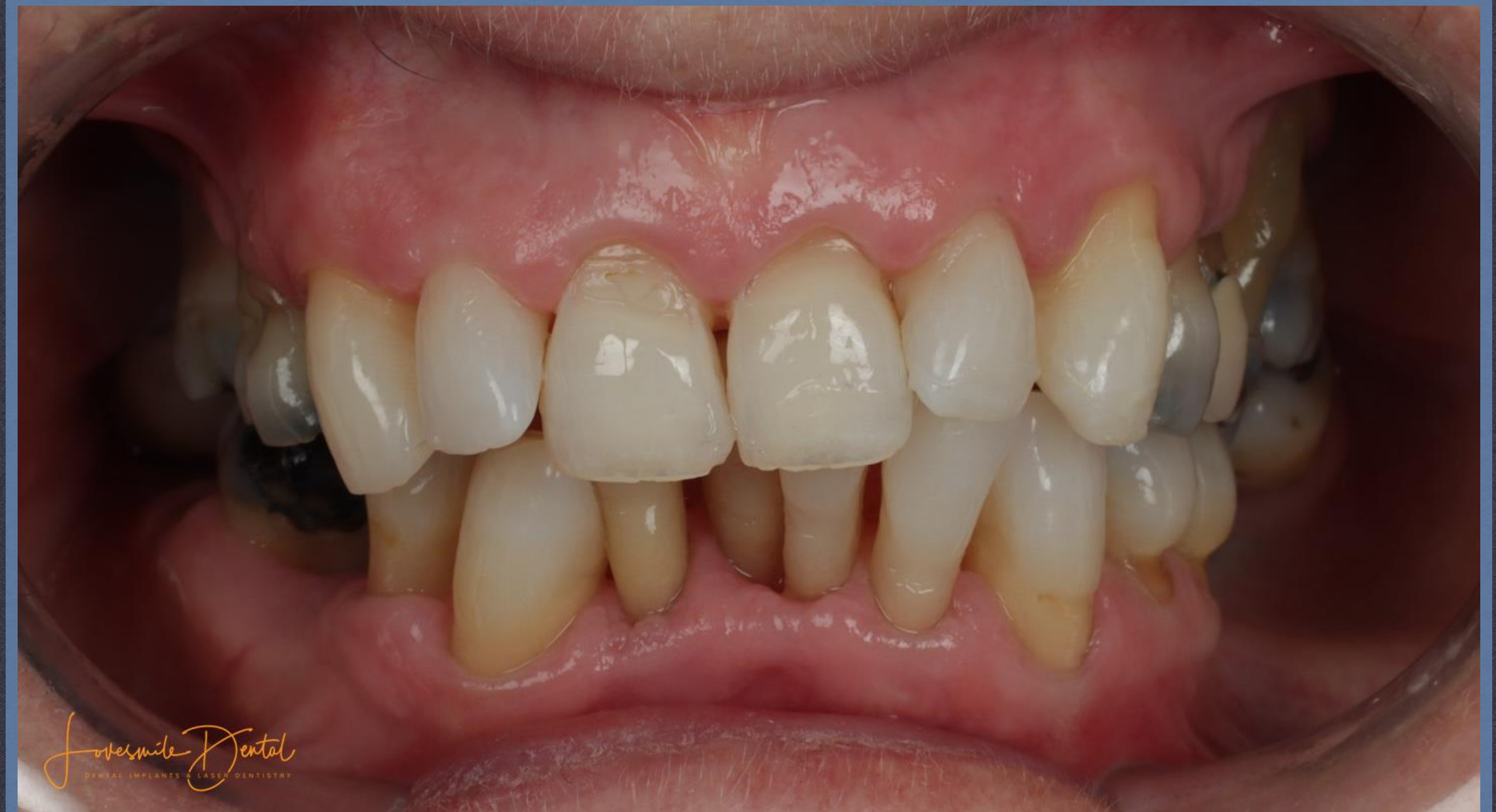
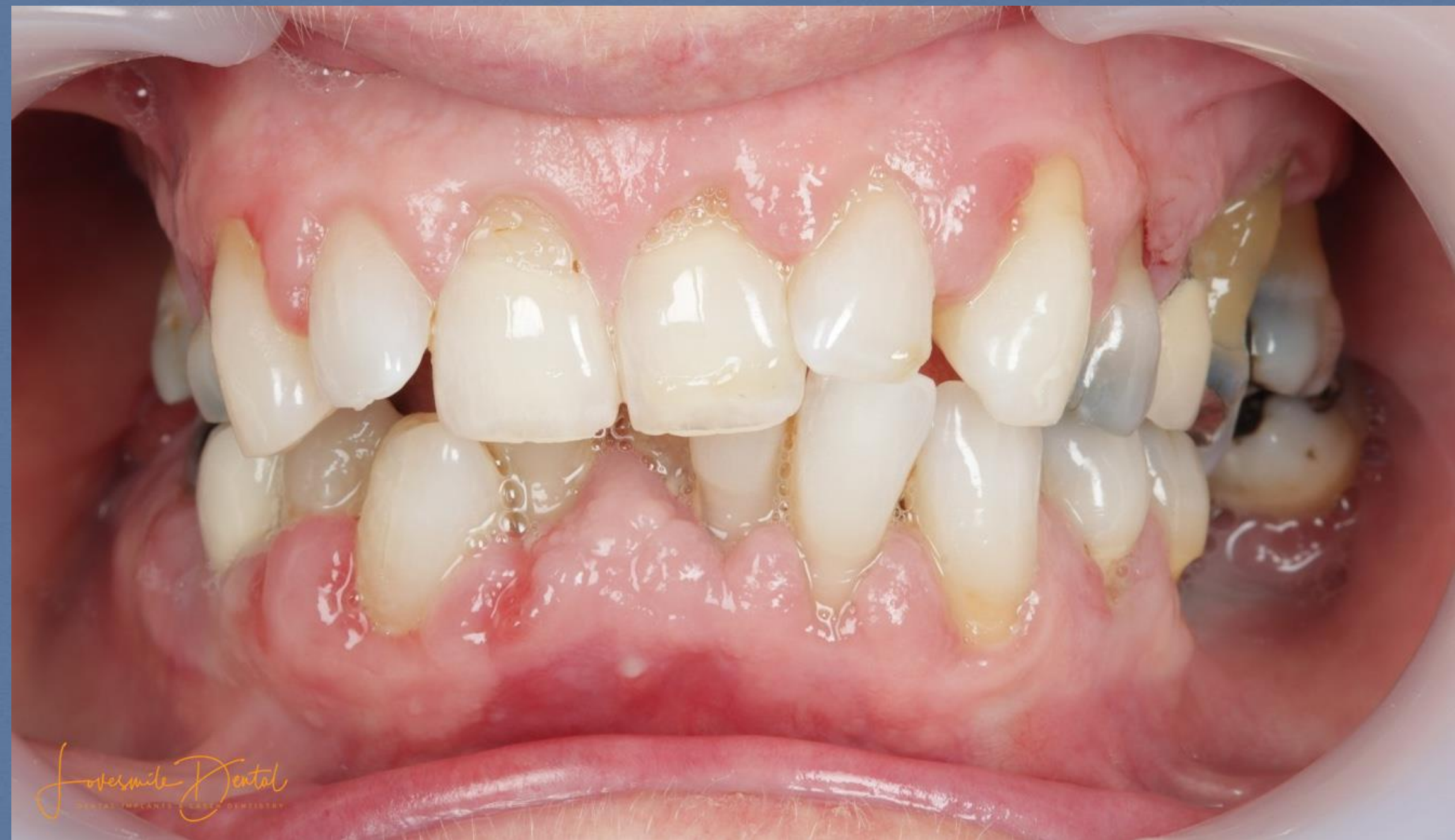
HEALTHY GUM MAINTAINED 1 YEAR AFTER TREATMENT

THERE IS NO SWELLING AND OBSERVE HEALTHY PINK GUMS EVEN AFTER A YEAR



BONE REGENERATION AROUND ROOT OBSERVED IN RADIOGRAPH DONE 1 YEAR AFTER TREATMENT



BEFORE AND AFTER